

Subvastus Approach for Total Knee Arthroplasty

Patient Positioning & Exposure

F. PRIGENT. Clinique Saint Louis. 78300 Poissy (France) - E-mail: contact@prigent.org

As minimally invasive total knee arthroplasty (TKA) was gaining popularity, several so-called "MIS" techniques have been developed.

The subvastus approach described hereunder provides excellent exposure through a mini incision. The two key aspects of this technique is that it preserves integrity of the vastus medialis obliquus (VMO), and it makes patella eversion unnecessary.

Preservation of muscles and capsule has two main goals : ensure better functional capacity after TKA, and decrease postoperative pain and bleeding.

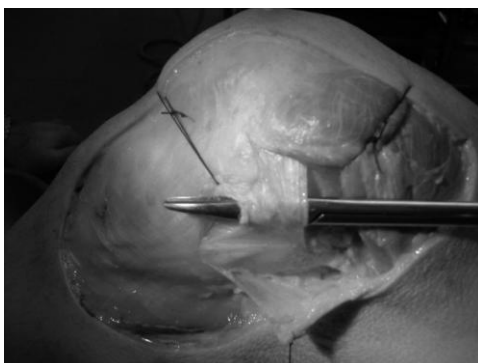
We will show hereunder how the technical difficulties due to the small incision and the tension exerted by the preserved muscles can be overcome.

Particular focus will be placed on anatomy of the VMO insertion site and the dissection procedure.

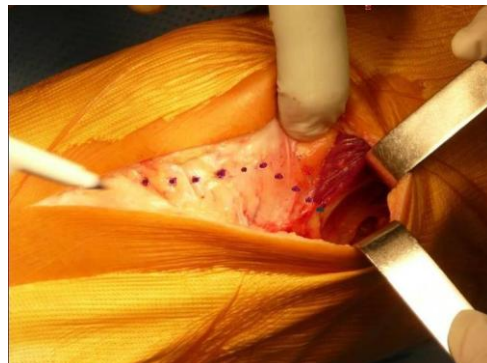
ANATOMICAL CONSIDERATIONS

With the increased use of MIS techniques, more attention has been paid to the vastus medialis obliquus (VMO) and several studies have been published. Some authors have located the inferior VMO attachment close to the superomedial pole of the patella. In more recent papers, it has been shown that VMO tendon fibers could be seen as far as the midpatella, on the medial edge of the patella (1,2). The VMO tendon is 1.2 to 2.2 cm long and forms an angle of 50°-60° with the longitudinal axis of the femur (1,2,3).

Attachment of the medial patellar retinaculum is also located on the medial edge of the patella. In its superior portion (medial patellofemoral ligament), the insertion site is overlaid by the VMO tendon (level 2). Their respective fibers get tightly entangled adjacent to the medial edge of the patella (4). The descending expansions of the quadriceps fascia which overlies these fibers create a superficial fibrous layer (longitudinal patellar retinaculum) (5).



Patellar retinaculum and VMO: level 2



Intraoperative view: level 1

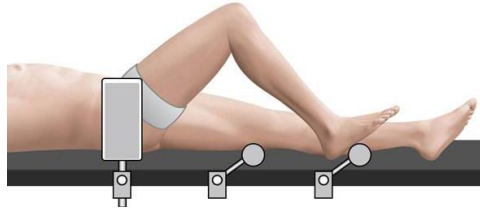
The VMO fibers provide a reliable landmark. The VMO tendon is in continuation with these fibers and attaches (under the protection of a fibrous tissue layer) to the midportion of the medial edge of the patella at an angle of 50°-60° (level 1).

SURGICAL TECHNIQUE

1/ Patient positioning

The patient is in a strict supine position.

A vertical thigh support maintains the affected leg in the correct position. The sole of the foot rests on one of the horizontal supports fixed to the side of the table.



This provides three positioning options:

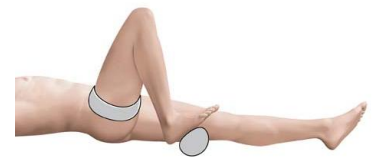Full extension, **90°** flexion, **110°-120°** flexion (deep flexion).



Full extension



90° Flexion



Deep flexion

2/ Instrument System

The use of instruments dedicated to MIS surgery is critically important. As a matter of fact, the success of the subvastus approach essentially relies on the use of mini cutting guides for some bone cuts. It is also very important that these instruments be familiar to knee surgeons. They should include one straight Hohmann, one curved Hohmann and standard retractors, and should complement a standard knee instrument system.



3/ Incision

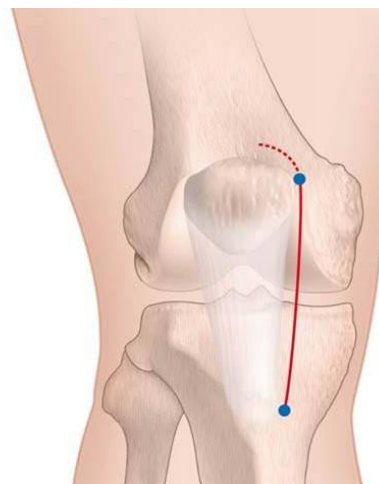
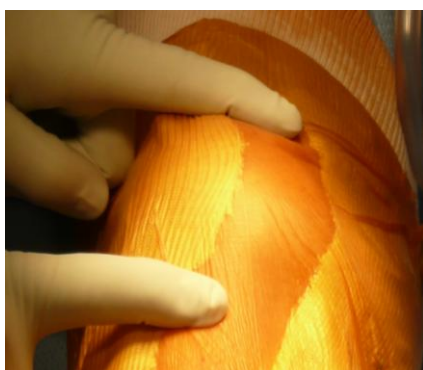
An accurate incision line will facilitate the approach.

Palpate the patella and anterior tibial tubercle on the extended knee.

Place an initial mark at the superomedial edge of the patella.

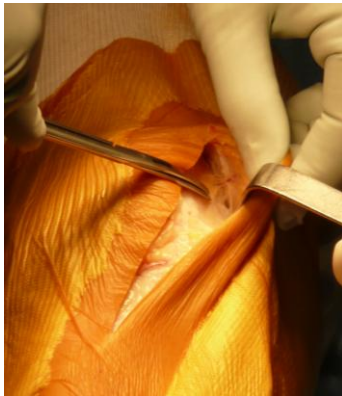Place a second mark medially at the tip of the tibial tuberosity.

Draw a line that connects these two points : the 10 cm long (approximately) skin incision should be made along this line and extended proximally for 2 cm in a gentle lateral curve.

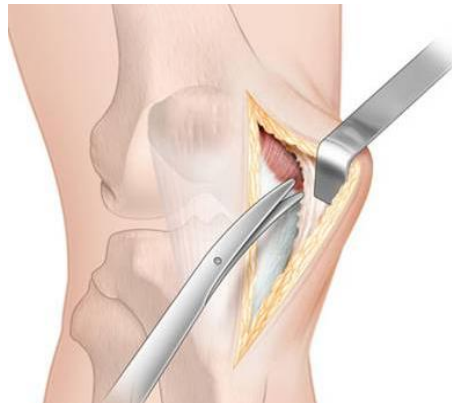


4/ Superficial layers

Incision of the cutaneous and subcutaneous fat layers is followed by blunt dissection (initially with scissors and then with a finger). Lift-off begins on the medial edge of the patella, in its mid-section, and extends into the superomedial portion of the incision, above the VMO. This provides an adequate entry portal that corresponds to a quarter circle of 5-6 cm diameter.

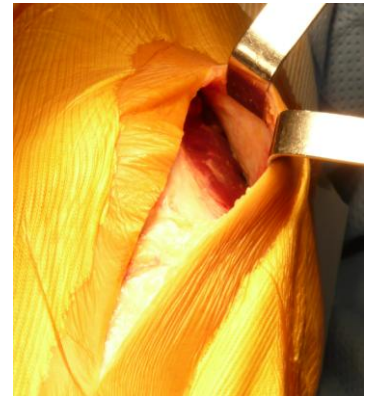


Blunt dissection is begun with scissors

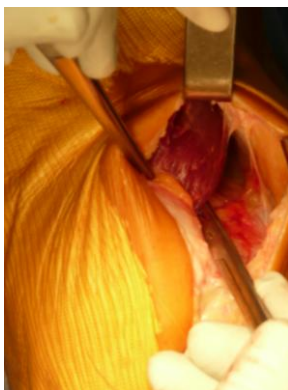


...

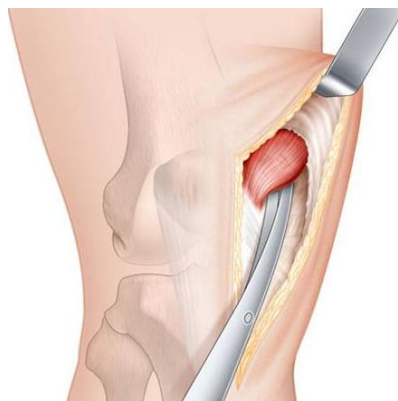
and continued with a finger to end up above the VMO



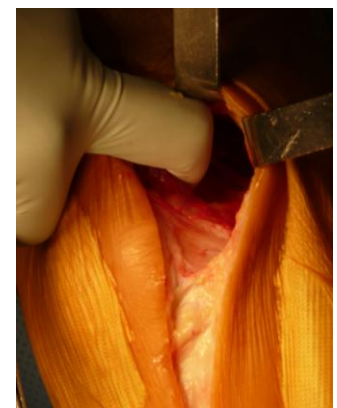
After identification of the inferior edge of the vastus medialis and incision of its thin fascia, raise the muscle off the medial intermuscular septum for a distance of 5 cm (first with scissors, then with a finger). Continue with blunt finger dissection of the muscle belly posteriorly to separate it from the underlying synovium. This is very easy because the posterior aspect of the VMO does not adhere to the synovium.



Scissor dissection of the vastus medialis

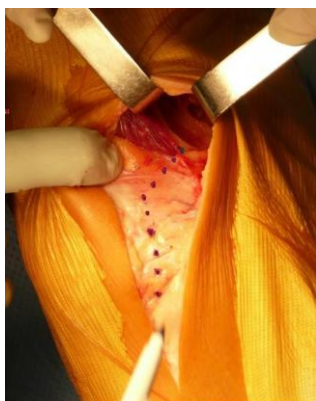


...

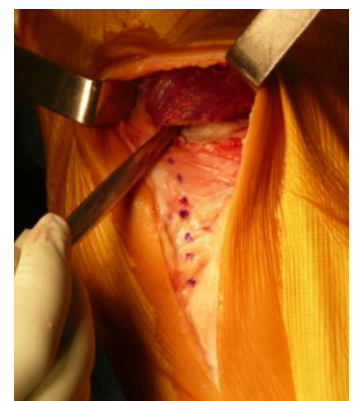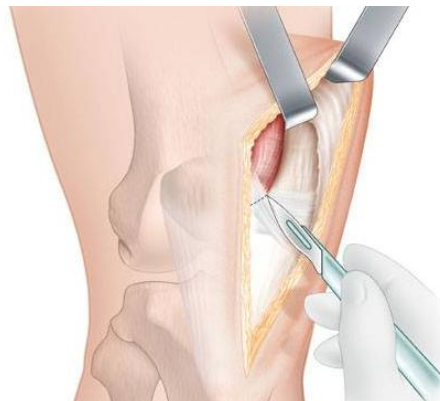


followed by finger dissection

Retract the belly of the VMO posteriorly using a Farabeuf retractor. The 1-2 cm long VMO tendon attaches to the medial edge of the patella at an angle of 50°-60°. Descending expansions of the quadriceps fascia unite with the medial patellar retinaculum and overlie the muscle. This 2 cm fibrous bridge is obliquely detached (50°-60°) from the VMO muscle fibers up to the tendon attachment onto the mid-section of the medial edge of the patella. Care should be taken to preserve integrity of the underlying synovium.



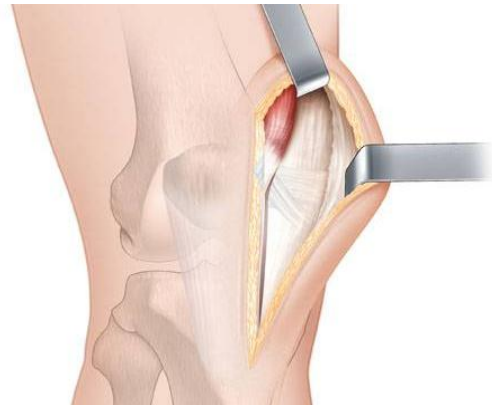
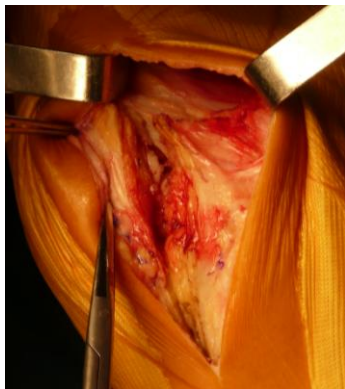Incision line



VMO free

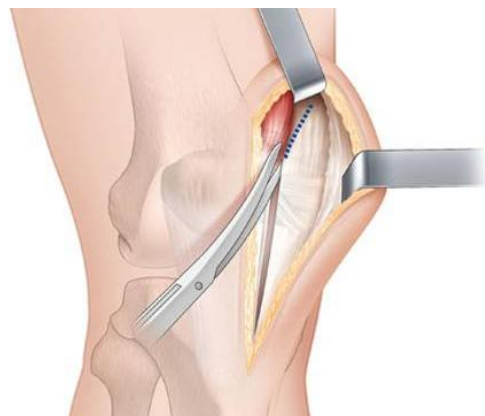
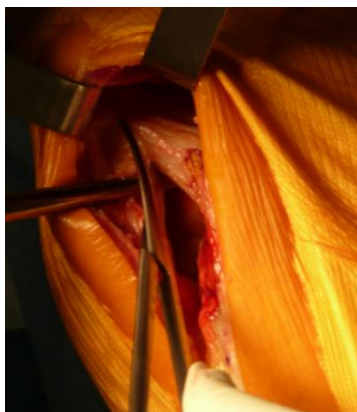
5/ Deep layers

Then, sharp dissection is performed vertically from the VMO tendon down to the patellar tendon insertion. Section the medial patellar retinaculum together with the synovium along the medial edge of the patella and patellar tendon. As they approximate the patella, these two structures tend to adhere to each other, which greatly facilitates closure at end of surgery.



Sharp dissection along the edge of the patella and patellar tendon

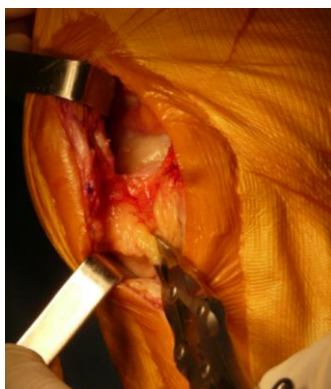Incision of the synovium is completed proximally with scissors along the medial edge of the suprapatellar pouch, under the VMO which is still laterally retracted. Place a tagging suture on the lateral edge of the synovial incision to facilitate identification during closure.



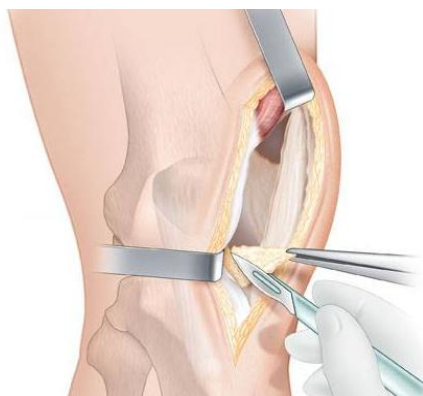
Incision of the suprapatellar pouch

Insert a Farabeuf retractor between the patellar tendon and the Hoffa fat pad. Excise most of the fat pad.

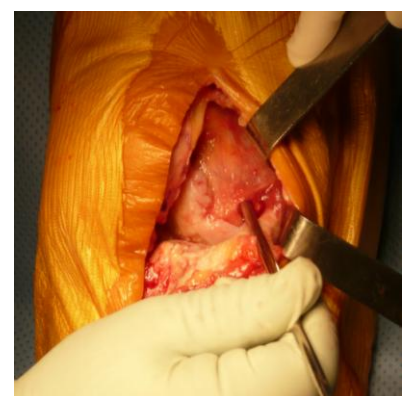
Insert a Steinman pin into the edge of the medial femoral condyle in an oblique proximal-medial direction, that is, 30° to the longitudinal axis of the femur with a 30 degree internal angle. It will serve as a medial retractor until component insertion.



Hoffa fat pad is retracted



and then removed

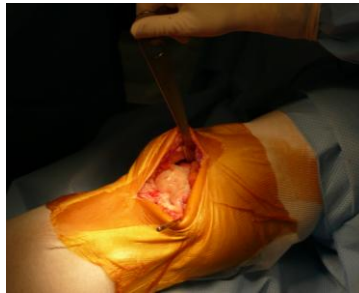

A Steinman pin is inserted into the medial femoral condyle

6/ Bone cuts

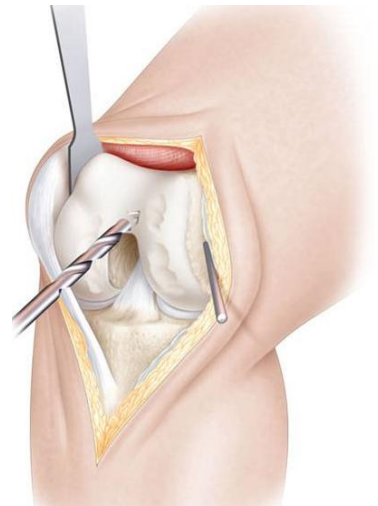
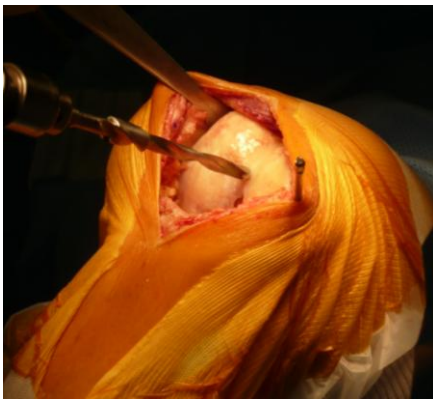Distal Femoral Cut

Place a straight Hohmann retractor along the superior border of the lateral femoral condyle. By resting on the VMO tendon, it maintains the extensor mechanism retracted laterally.



Place the knee in 90 degrees of flexion.

Resect the anterior portion of both menisci to get full visualization of the posterior condyle line during the next step. Drill the femoral medullary canal.

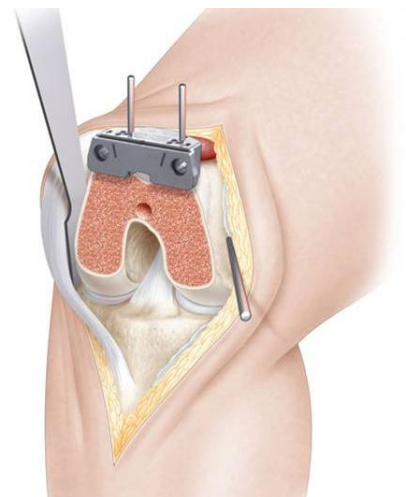
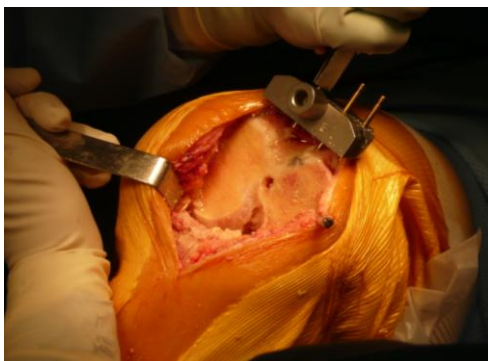


Insert the intramedullary (IM) rod into the medullary canal.

Place and secure the distal cutting guide that has been set to the appropriate resection level.

Exposure can be greatly improved by placing a Farabeuf retractor along the lateral femoral condyle in order to retract the VMO fibers proximally.

The distal femoral cut can be performed.



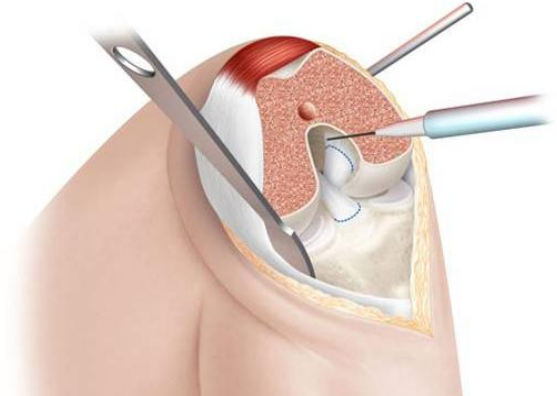
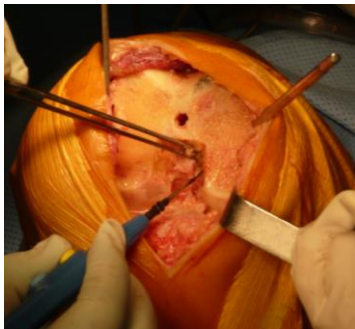Resection of both cruciates



Move the Hohmann retractor to the edge of the lateral tibial condyle.

If held vertically, it maintains the patella retracted laterally.

Bring the knee into full flexion with the sole of the foot resting on the second horizontal support. Remove any femoral notch osteophytes, release the anterior cruciate ligament (ACL) from its attachment to the proximal tibia, release the posterior cruciate ligament (PCL) from its attachment to the superomedial aspect of the femoral notch. Resect both cruciates.



Superior attachment of the PCL and inferior attachment of the ACL are released

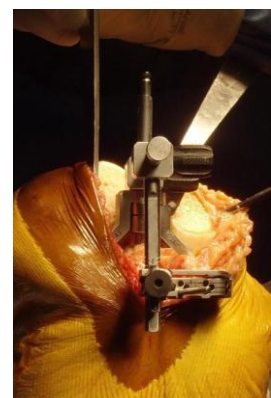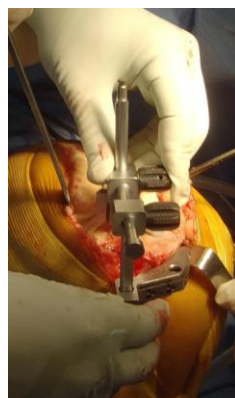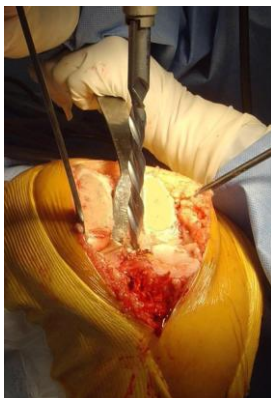
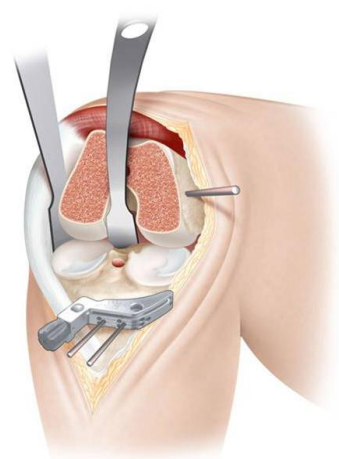
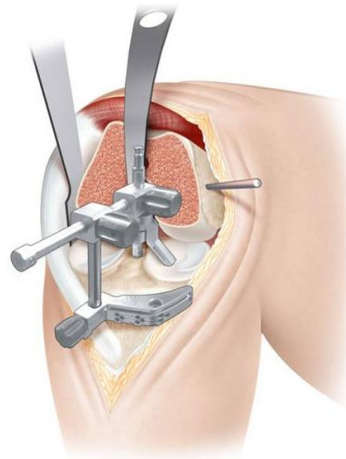
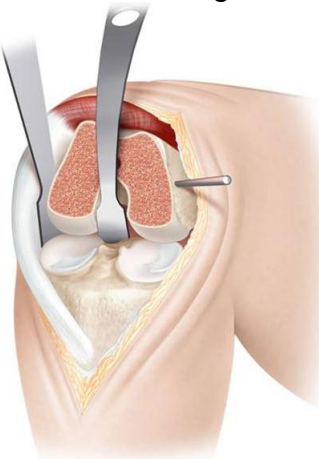
Proximal tibial cut

The tibial cut is performed with the knee fully flexed.

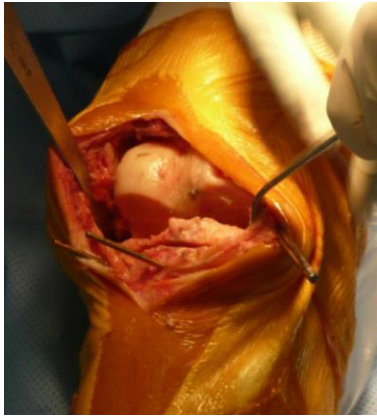
Insert a curved Hohmann retractor behind the tibial plateau to produce anterior translation while the straight Hohmann remains in position along the edge of the lateral tibial condyle.

Position the extra- or intramedullary tibial cutting guide and determine the tibial resection level.

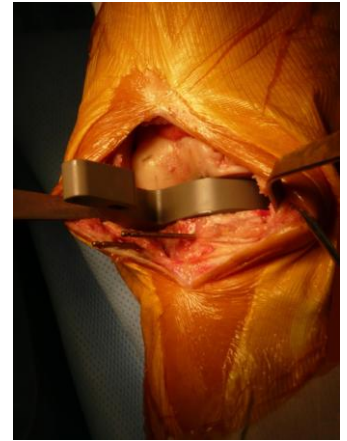
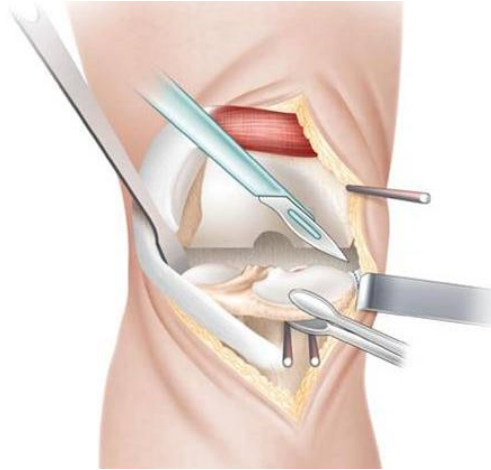
Placing a Farabeuf retractor on the medial side before initiating the tibial cut protects the medial collateral ligament (MCL).



Once the tibial cut has been performed, place the leg in extension, which facilitates removal of the resected bone. Gentle axial traction is sufficient to open the joint space. Then, use powerful forceps to grasp and pull the medial bone fragment while the posterior aspect of the tibial plateau is cautiously freed with a scalpel. Then, insert a tibial spacer to ensure that enough tibial bone has been removed. Copiously irrigate the knee while in extension.



the tibial plateau is freed



the tibial spacer



7/ Additional bone cuts

Anterior femoral cut

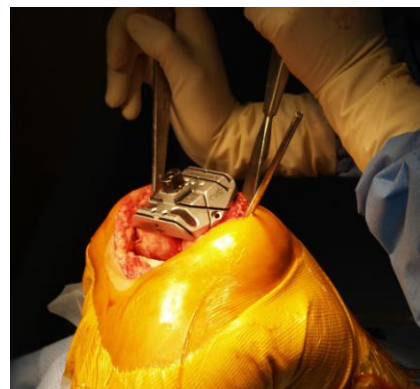
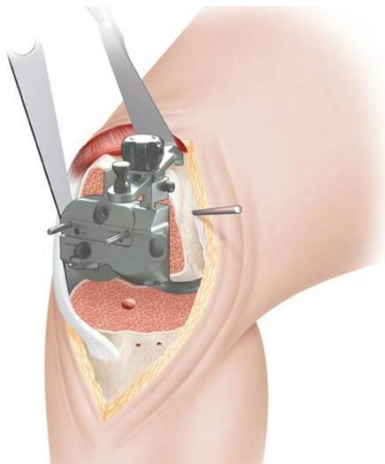
Bring the knee back to 90° flexion using the first horizontal support.

The straight Hohmann retractor is still in position on the lateral side of the proximal tibia.

Place a retractor that will provide exposure of the anterior aspect of the femur, proximal to the trochlea.

Apply the 4-in-1 femoral cutting guide to the resected distal femur.

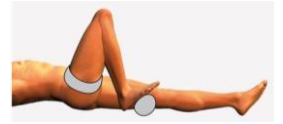After incision of the synovium, allow the femoral stylus to rest on the anterior cortex in order to determine the appropriate size of the femoral component.



The anterior femoral cut is performed first.

For all other femoral cuts, the anterior retractor should be replaced by a Farabeuf retractor that is successively placed on the medial side and on the lateral side. Remove all resected bone fragments and insert the femoral notch guide to prepare for the femoral box.

Tibial tray



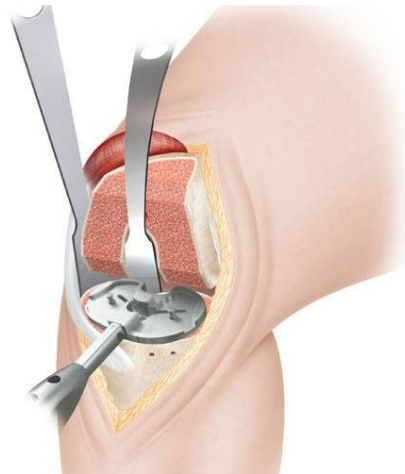
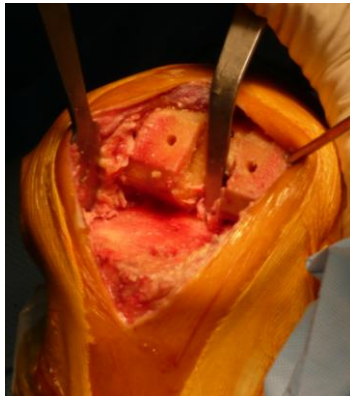Place the knee in deep flexion.

Remove the remnants of the menisci and resect any posterior osteophytes.

The lateral Hohmann retractor is still in place.

Return the curved Hohmann retractor to its posterior position, behind the proximal tibia.

Place the trial tibial tray onto the resected tibial surface for preparation of the tibial keel housing.



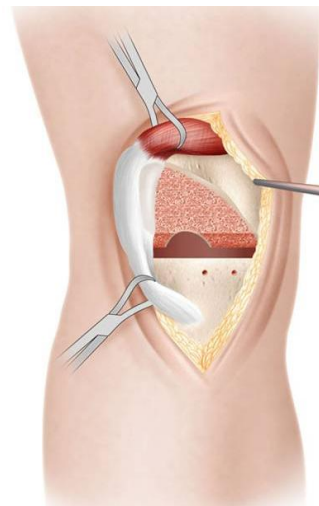
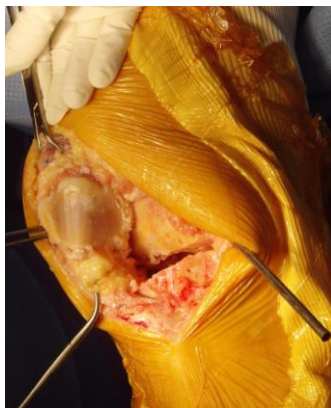Resection of the patella

The knee is extended and both retractors are removed.


Bring the patella into the incision and hold it with two forceps.

Position the patella resection guide onto the patella. Resect the patella and drill peg holes.

Copiously irrigate the knee joint.



8 / Component implantation

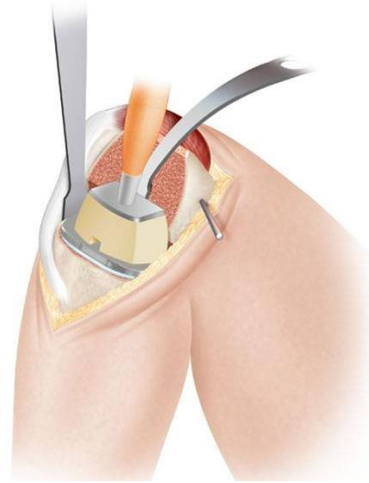
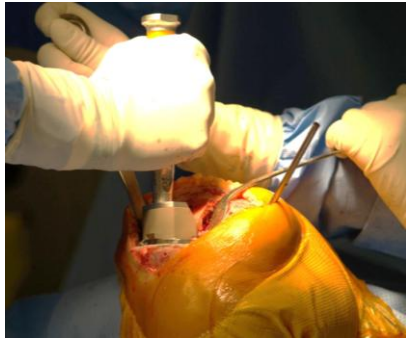
Tibial tray

Place the knee in deep flexion with the sole of the foot resting on the second horizontal support.

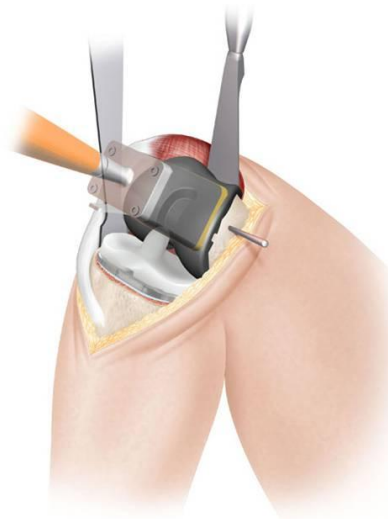
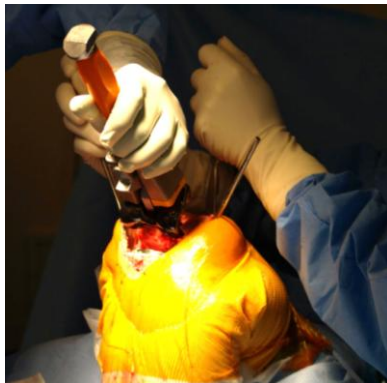Return the two Hohmann retractors to their lateral and posterior positions respectively.

Sublux the tibia anteriorly. Impact the tibial tray until fully seated.



Femoral component

Leave the knee in deep flexion with the foot on the second horizontal support. Leave the straight Hohmann retractor in place on the lateral side. Replace the curved Hohmann retractor by a Farabeuf-type anterior retractor to retract the vastus medialis fibers proximally and facilitate insertion of the femoral component.

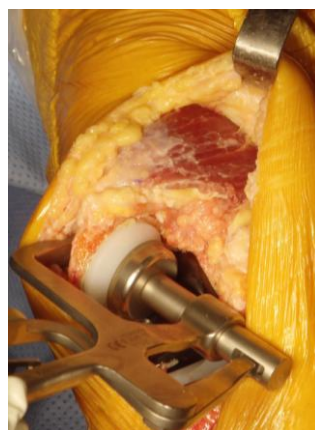


Place the polyethylene tibial bearing onto the tibial tray and snap it in while slowly bringing the knee into extension.

Patellar component



While the patella is firmly held with two forceps, cement the patellar component.

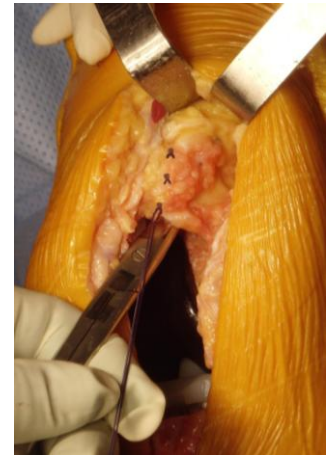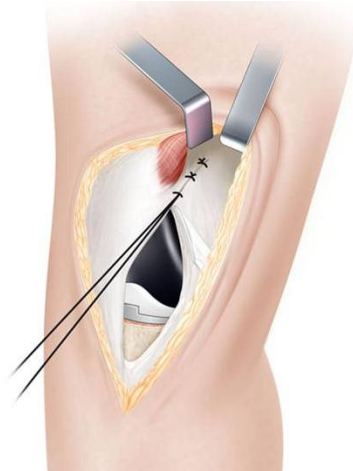

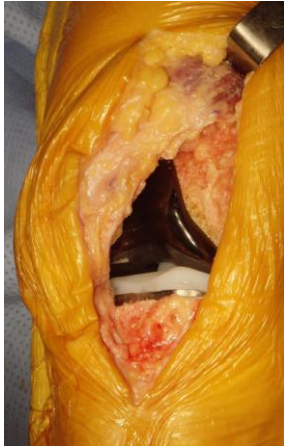
9 / Closure

Freely irrigate the wound with the knee in extension.

Deflate the tourniquet and control bleeding.

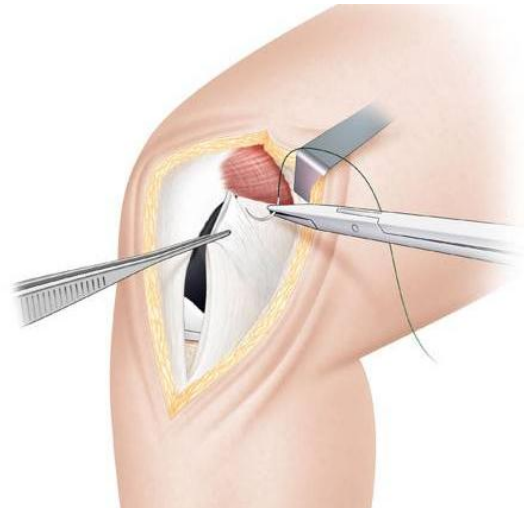
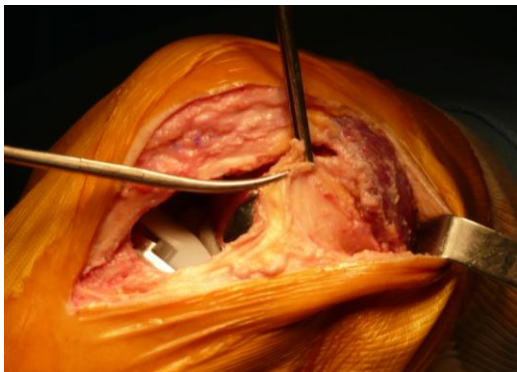
With the vastus medialis retracted, close the suprapatellar synovial pouch using 3 interrupted sutures. The tagging suture facilitates identification of its lateral edge.



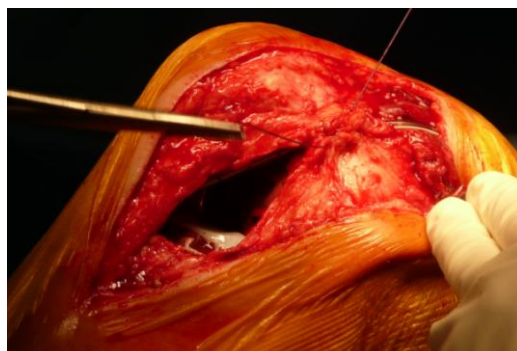
Place the knee in 90° flexion with the foot resting on the first horizontal support.

Closure of the joint is very simple, indeed : reattach the medial patellar retinaculum and underlying synovium to the medial edge of the patella.

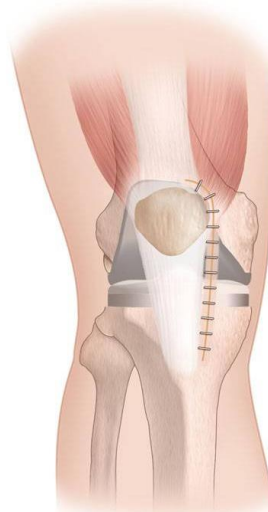
First, place a strong suture at the proximal end of the incision, between the superior corner of the retinaculum and the inferior insertion of the VMO tendon.



Then, work down to the inferior end of the incision, closing the retinaculum and the synovium with interrupted sutures.



Place subcutaneous interrupted sutures and close the skin with staples.



HINTS and TIPS

Minimally invasive surgery requires great caution at all times.

- If the incision is too small, cutaneous complications may result (i.e. skin necrosis, contact between the implant and the skin) and provide an entry portal for infection. The initial incision can be extended at any stage of the procedure.
- An insufficient gap between the cutaneous/subcutaneous fat layers and the anterior aspect of the VMO makes it difficult to retract the extensor mechanism laterally. On the other hand, an excessive gap may cause injury to branches of the saphenous nerve (6).
- Release of the VMO tendon is a critical step. The incision should extend from the end fibers of the VMO to the midportion of the medial edge of the patella. A longer incision that would reach the superomedial pole of the patella would detach the tendon and the approach would no longer be subvastus.
- Closure of the suprapatellar synovial pouch preserves all sliding sheaths. During exposure, identifying the lateral edge with a tagging suture facilitates closure of the capsule at end of the procedure.
- Correct component positioning is critical. A few common errors have been reported in the literature (7).
 - The tibial and femoral cutting guides must be securely fixed to the bone. Due to their small size, they are more prone to shifting during resection. Furthermore, the pressure exerted by soft tissue (i.e. patellar tendon and VMO) may modify their orientation.
 - The lateral tibial condyle must be fully visualized to avoid underresection of the proximal tibia.
 - On the femoral side, a longitudinal incision of the anterior synovium facilitates positioning of the femoral sizer and allows better control of the anterior femoral cut. A perfect exposure of the distal femur is mandatory to allow identification of the landmarks used for rotational alignment : Whiteside line, posterior condyle line, transepicondylar axis.
- Care should be taken to protect the medial collateral ligament (MCL) with a medial retractor during resection.
- During closure, placement of sutures and tightening of the medial retinaculum should be performed with the knee flexed 90° to avoid iatrogenic patella baja.
- Due to early mobilization, it is wiser to close the skin with staples than with continuous suture.
- If a tourniquet is used, it should be placed at the root of the thigh and inflated with the knee flexed to 90° to facilitate mobilization of the vastus medialis.

- At the end of the procedure, accurate hemostasis should be created with the tourniquet deflated to control bleeding in the posterior VMO lift-off area.
- Thanks to the two horizontal supports, the position of the leg can be adjusted as required during the procedure. The operating surgeon, the scrub nurse and the assistant are familiar with the use of these helpful accessories.

LIMITATIONS OF THE TECHNIQUE

Due to the small size of the incision, the subvastus approach is not suited for revision surgery which requires full visualization of the operative site.

The subvastus approach is not recommended for patients with preoperative flexion limited to 90 degrees or with patella baja, because this makes exposure much more challenging and carries a high risk of patellar tendon detachment on forced flexion.

It is also recommended to reserve the subvastus approach for patients with valgus/varus deformities less than 15 degrees. As a matter of fact, severe deformities require additional procedures which cannot be performed through a small incision.

Overweight is not a contraindication by itself. It just requires extension (a few centimeters) of the initial incision. Capsule and muscle dissection can still be performed using a minimally invasive technique.

CONCLUSION

A surgeon who is familiar with the standard parapatellar arthrotomy may not feel at ease when working through a small incision that offers limited visual control. But a precise exposure technique, a clear sequence of surgical steps, and the use of dedicated instruments will help him overcome this inconvenience.

The above technique has one key advantage: preservation of the muscles and capsule by sparing the vastus medialis and closing the capsule at end of surgery. By gradually gaining familiarity with the technique, any knee surgeon should be able to achieve accurate and reproducible positioning of the components without increasing the complication rate.

In case of intraoperative difficulty, the knee can be placed in extension at any stage of the procedure.

Most surgeons find that the subvastus approach ensures faster recovery of function which (according to some of them) is associated with less postoperative pain.

This surgical approach provides more inherent stability to the patellofemoral joint due to preservation of the VMO and repair of the patellar retinaculum.

1. Pagnano MW, Meneghini RM, Trousdale RT (2005) Anatomy of the extensor mechanism with particular reference to minimally invasive total knee arthroplasty. Metting of the knee society; 2005 Sep; New York.
2. Andrikoula S, Anastasios T, and al. (2006) The extensor mechanism of knee joint : an anatomical study. Knee Surg Sports Traumatol Arthrosc. 2006 march; Vol 14, n° 3: 214-220.
3. Bassam A, Masri MD, and al. (2007) Mini-subvastus approach for minimally invasive total knee replacement. Tech in knee surg. 2007; 6(2) : 124-130..
4. Aragao JA, Reis FP, and al; (2008) Metric measurements and attachment level of the medial patellofemoral ligament : an anatomical study in cadavers. Clinics. 2008 ; Vol 63 n° 4 .
5. Beauchier JP, Lefevre P (2003) Traité d'anatomie. Edition Deboeck. 117-118.
6. Witvoet J. (2002) Voies d'abord de l'arthroplastie prothétique du genou. Cahier d'enseignement de la SOFCOT 81. Prothèses totales du genou. 2002. 71-83.
7. Dalury DF, Dennis DA (2005) Mini-incision total knee replacement can increase risk of component malalignment. Clin Orthop Relat Res. 2005; 440 : 77-81